



# **BRITISH** **MEDICAL JOURNAL**



## British Medical Journal

### Volume 1, No 2., 2021

Internet address: <http://ejournals.id/index.php/bmj>

E-mail: [info@ejournals.id](mailto:info@ejournals.id)

Published by British Medical Journal

Issued Bimonthly

3 knoll drive. London. N14 5LU United Kingdom

+44 7542 987055

Chief Editor

**Dr. Fiona Egea**

#### *Requirements for the authors.*

*The manuscript authors must provide reliable results of the work done, as well as an objective judgment on the significance of the study. The data underlying the work should be presented accurately, without errors. The work should contain enough details and bibliographic references for possible reproduction. False or knowingly erroneous statements are perceived as unethical behavior and unacceptable.*

*Authors should make sure that the original work is submitted and, if other authors' works or claims are used, provide appropriate bibliographic references or citations. Plagiarism can exist in many forms - from representing someone else's work as copyright to copying or paraphrasing significant parts of another's work without attribution, as well as claiming one's rights to the results of another's research. Plagiarism in all forms constitutes unethical acts and is unacceptable. Responsibility for plagiarism is entirely on the shoulders of the authors. Significant errors in published works. If the author detects significant errors or inaccuracies in the publication, the author must inform the editor of the journal or the publisher about this and interact with them in order to remove the publication as soon as possible or correct errors. If the editor or publisher has received information from a third party that the publication contains significant errors, the author must withdraw the work or correct the errors as soon as possible.*

#### **OPEN ACCESS**

Copyright © 2021 by British Medical Journal

**British Medical Journal** Volume-1, No 2

## **Indicators x-ray Densitometric studies in fractures of long tubular bones with the use of plasma lifting in an experimental study**

<sup>1</sup>Gafforov A.U., <sup>2</sup>Asilova S.U., <sup>3</sup>Teshaev A.A.

1, 3Department of Traumatology and Orthopedics and Pediatric Surgery,  
Bukhara State Medical Institute named after Abu Ali ibn Sino, Bukhara, Uzbekistan

<sup>2</sup> Department of Traumatology and Orthopedics, Tashkent Medical Academy,  
Tashkent, Uzbekistan

**Abstract:** x-ray (densitometric) studies were performed on 60 Chinchilla rabbits at 7,14,21,30,60 and 90 days after modeling the fracture of the femoral shaft of the hind leg. The animals were divided into 2 groups. Rabbits of experimental group 1 did not receive specific therapy after modeling the fracture. Postoperative wounds were treated daily with a solution of betadine. Animals of experimental group 2 were injected weekly with 1 ml of platelet-rich plasma along the perimeter of the wound. The results of the conducted studies allowed us to establish that in the main group, the restoration of bone defects occurs according to the type of complete healing. Control X-rays confirm intensive bone formation during OTP injections and signs of osseointegration: bone tissue without signs of inflammation, no signs of rarefaction of bone tissue.

**Keywords:** X-ray (densitometric) studies, experiment, rabbits, chinchilla breeds, plasmolifting, fracture, long cadaverous bone.

**Relevance:** According to the data, platelet-rich autoplasm was used for surgical treatment of patients with bone and cartilage defects, in order to optimize the processes of reparative osteo - and chondrogenesis, this technique helped to improve the results [2, 33, 34, 35]. The authors also used plasmolifting for comminuted intra-articular fractures, avoiding their removal or fixation with implants of cartilage fragments with subchondral bone [3, 31, 32, 33].

Other authors used growth factors in patients with arthroscopy of the shoulder joint due to damage to its rotator cuff, as well as when replacing the cuff defect with a membrane from autologous fibrin saturated with growth factors. The authors obtained positive results after 6 months, which consisted in reducing the intensity of the pain syndrome and healing the shoulder cuff defect[8, 9, 27, 28, 29, 30]. The author and author wrote in 14 patients and obtained promising sustained results following a 24-month follow-up of safety and results of shoulder rotator repair using growth factors in a pilot study [10, 21, 22, 23, 24].

According to the data, the use of platelet concentrate injections in the treatment of osteoarthritis of the knee joint. The authors wrote that using B quality control injections of hyaluronic acid, and showed better analgesia and physical improvement in function when using plasmolifting[11, 14, 20, 25, 26].

However the author did not conduct studies in acute trauma i.e. in diaphyseal fractures of the lower leg and the method of treating patients with the use of plasmolifting[1, 3, 4, 16, 17, 18, 19].



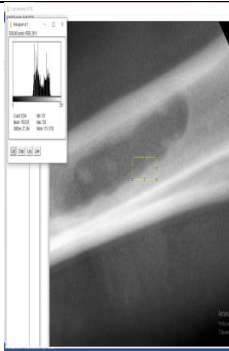
**Objective:** to study the parameters of densitometric studies in fractures of long tubular bones using plasma lifting in an experimental study.

**Materials and methods:** X-ray (densitometric) studies were performed on 60 Chinchilla rabbits at 7,14,21,30,60 and 90 days after modeling the fracture of the femoral shaft of the hind leg [5, 7, 6, 15, 16]. The animals were divided into 2 groups. Rabbits of the experimental group 1 did not receive specific therapy after modeling the fracture. Postoperative wounds were treated daily with a solution of betadine. Animals of the experimental group 2 were injected weekly with 1 ml of platelet-rich plasma along the perimeter of the wound.

Digital images of the experimental animals were processed on a personal computer using the Image J program (Wayne Rasband. National Institute of Health, USA. <http://rsb.info.nih.gov/ij>). This program is designed for the analysis of scientific images. The results are displayed as a histogram with the average values.

According to the results of X-ray studies, it was found that at the time of the surgical intervention, there were clear contours of the femur (Fig. 1), the bone tissue around the operating bed without pathological changes, there were no signs of an inflammatory process in the bone tissue (Fig.2, 3).

According to the results of X-ray examinations, it was found that at the time of the surgical intervention, there were clear contours of the femur (Fig. 1), the bone tissue around the operating bed without pathological changes, there were no signs of an inflammatory process in the bone tissue (Fig.2, 3).

		
Fig. 1 X-ray picture of the femoral shaft of the hind leg of a rabbit before modeling the fracture	Fig. 2. X-ray image of the femoral shaft of the rabbit hind leg after modeling the fracture	Fig. 3 Densitometric parameters of rabbit bone tissue on day 7 of fracture modeling

The results of the study of the dynamics of the regeneration process of bone fractures in rabbits of groups 1 and 2 on day 14 showed that there were no significant differences between the compared groups (Fig. 4,5). Dynamic monitoring of the state of bone regeneration in the area.




Fig. 4. Radiological and densitometric parameters of rabbits of group 1 on day 14

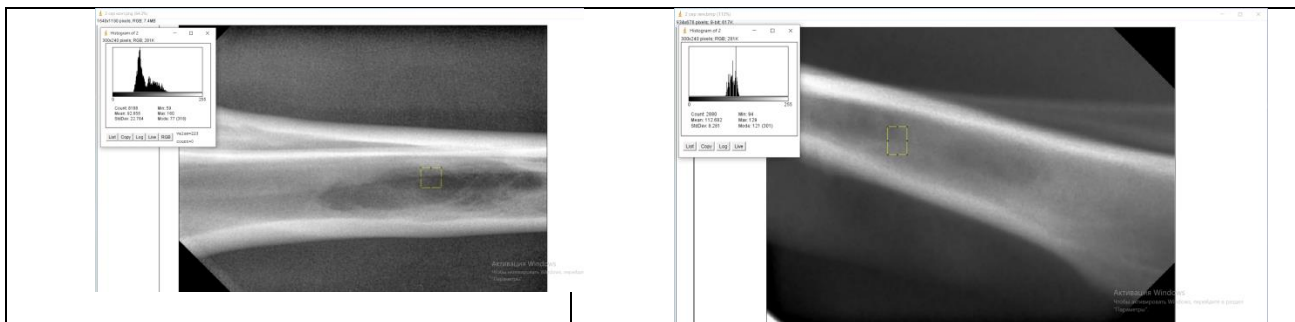


Fig. 5. Radiological and densitometric parameters of rabbits of group 2 on day 14

experimental fractures after 7,14,21,30,60 and 90 days showed that clear, clearly detectable differences were observed on 21 days of experiments in animals of the 2 experimental group that were administered OTP. Densitometric parameters at 21 days (147,122 cu) were comparable with the initial values before the operation (134,135 CU). Stabilization of the process is recorded in group 2, starting from 30 days. Bone regeneration is more pronounced in comparison with the indicators of group 1. So, in rabbits of group 1, densitometric indicators for 21 days were 125,439 cu (134,135 CU in group 2). This trend is noted on X-ray images and confirmed by the results of densitometric studies (Fig. 6-7).

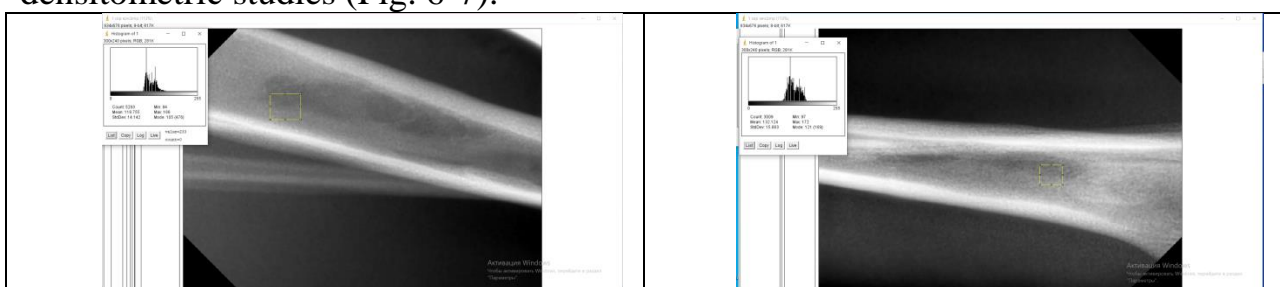


Fig. 6. Radiological and densitometric parameters of bone tissue in rabbits of group 1 for 21 days



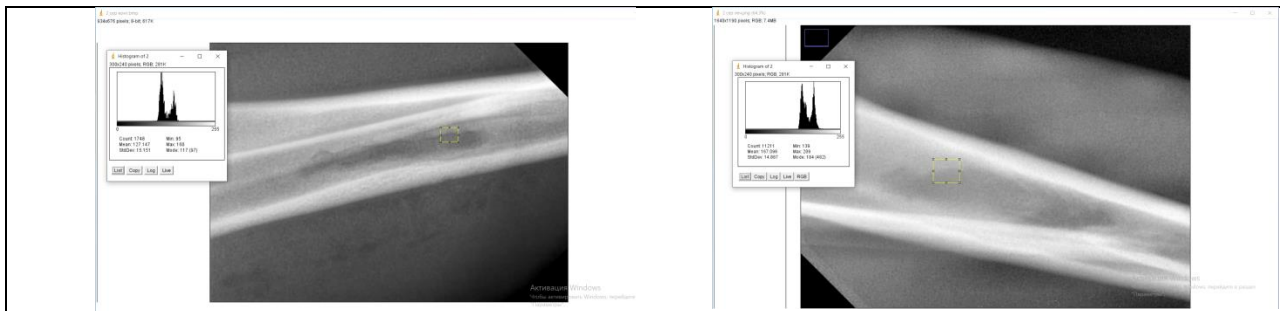


Fig. 7. Radiological and densitometric parameters of bone tissue in rabbits of group 2 on day 21

Figure 8 shows radiographs and results of densitometric studies of bone tissue in rabbits of group 1 30 days after surgery. There is a blurring of the contours, the formed tissue is visually homogeneous, and only in some areas the trabecularity of the structure of the newly formed bone tissue is determined. In rabbits of group 1, densitometric indicators on day 30 were 137,122 units .




Figure 8. Radiological and densitometric parameters of bone tissue in rabbits of group 1 on day 30

In rabbits of group 2, on day 30, the newly formed bone tissue was mainly of a small-cell trabecular structure, densitometric indicators were 131.567 cu (Fig. 9).

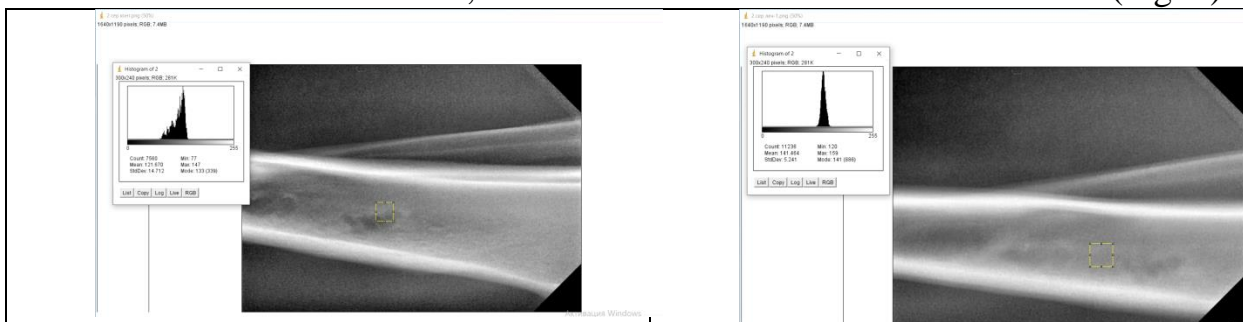
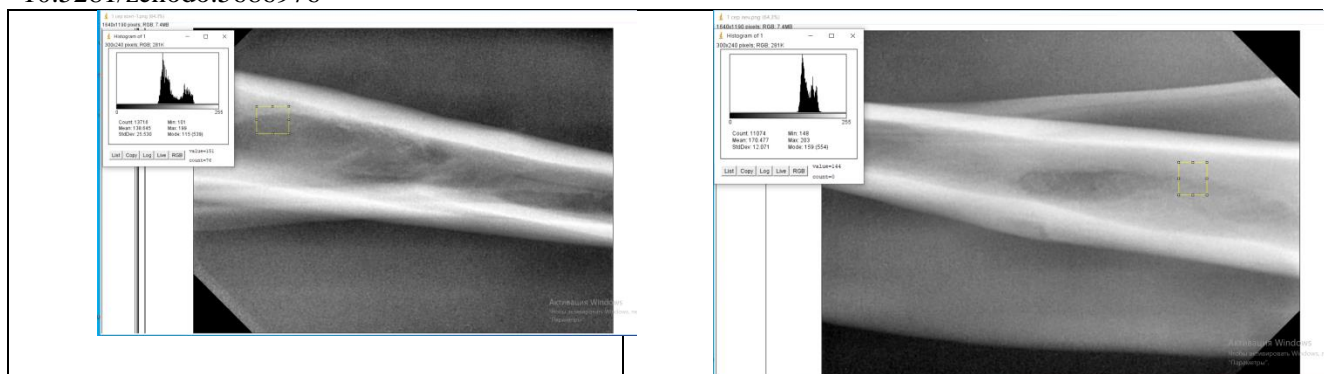


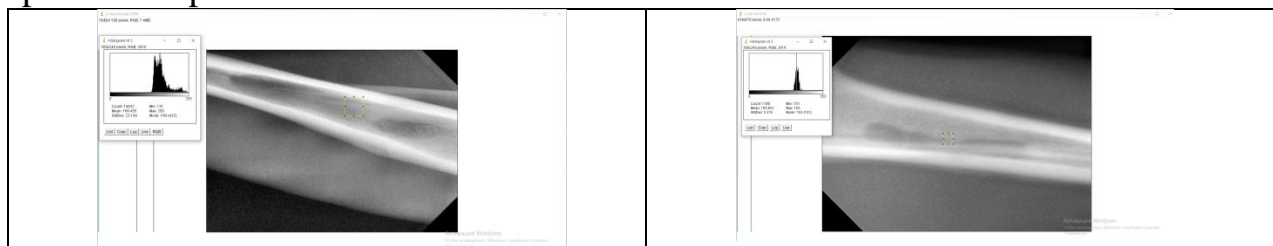
Fig. 9. Radiological and densitometric parameters of bone tissue in rabbits of group 2 on day 30

The average values of the densitometry index in group 1 on day 60 corresponded to 154.561 CU, i.e., the increase in the indicator is only 1.13 times in 30 days (Fig. 10).



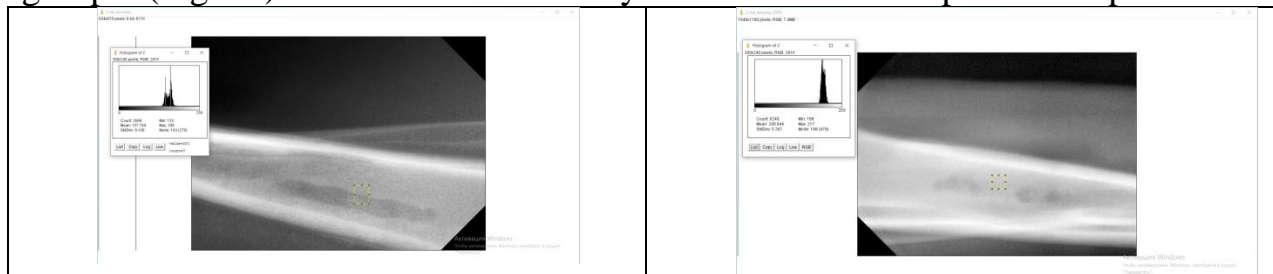
10. Radiological and densitometric parameters of bone tissue in rabbits of group 1 on day 60

A different dynamics of the acceleration of regeneration processes is recorded on day 60 in group 2. Thus, the average densitometry indicators were 166.053 CU (Fig. 11), which is 1.26 times higher than the same indicator for 30 days, and 1.07 times higher than the data of group 1. Bone regeneration is more pronounced in comparison with the indicators of group 1. This trend is obviously related to the positive impact of OTP.




11. Radiological and densitometric parameters of bone tissue in rabbits of group 2 on day 60

On day 90, the studied parameters in rabbits of group 1 were lower than in group 2. In group 2 animals, there is a tendency to accelerate the processes of bone fracture regeneration on the 90th day. At the site of surgery, there is a newly formed bone tissue with a trabecular pattern, completely identical to the surrounding bone tissue. (Fig.12). Bone regeneration is more pronounced in comparison with the indicators of group 1 (Fig. 13). This trend is obviously associated with the positive impact of OTP.



12. Radiological and densitometric parameters of bone tissue in rabbits of group 1 on day 90



13. Radiological and densitometric parameters of bone tissue in rabbits of group 1 on day 90

Analysis of the results of X-ray and densitometric studies in group 2 allowed us to establish a direct relationship between the increase in bone density and the time elapsed since the operation. The increase in osteoreparative processes in the operating field is reflected in the average increase in the X-ray density of the bone. Positive dynamics of osseointegration processes is achieved by 30-60 days).

The obtained X-ray data indicate the presence of bone tissue in the area of surgical intervention in the third month of the study. This is consistent with the data of Robustova T. G. (2005), who reports the presence of fine-grained bone in 1-2 months after the operation. Although the density of the newly formed bone during this period is less than the control value, after 3 months it approaches that of its own bone.

Thus, according to the results of X-ray examination and densitometry, it is possible to assert the positive dynamics of the processes of osseointegration using platelet-rich plasma.

The study showed a positive trend of dynamic increase in the density of the newly formed bone in different periods of the study. To determine the dynamics of the process of bone regeneration, we recommend conducting an X-ray visigraphic study with a computer analysis of X-ray images.

For an objective assessment of the degree of bone loss and the density of the newly formed bone in the well, we recommend using the ImageJ program (Wayne Rasband. National Institute of Health, USA)

Thus, the results of the X-ray (densitometric) studies allowed us to establish that in the main group, the restoration of bone defects occurs according to the type of complete healing. Control X-rays confirm intensive osteogenesis during OTP injections and signs of osseointegration: bone tissue without signs of inflammation, no signs of rarefaction of bone tissue.



## References

1. Abdusalamov I.S. Surgical treatment of fractures of long bones in the acute period of traumatic disease: author. dis. ... Cand. med. Sciences / Abdusalamov I.S. - M., 2001, - 26 p. [in Russian]
2. Brekhov VL (2007) Surgical treatment of patients with bone and cartilage tissue defects using platelet-rich autoplasm Medical Dissertations <http://medical-diss.com/>. [in Russian]
3. Gonarthrosis with autologous platelet-rich plasma // Modern technologies in medicine. - 2012. - №1. - with. 97-100. [in Russian]
4. Malanin D.A., Demkin S.A., Demeshchenko M.V. et al. Platelet-rich autologous plasma in the treatment of patients with stage 2 knee osteoarthritis // Genius of Orthopedics. - 2017. - T.23. - No. 1. - with. 44. [in Russian]
5. Panov A.A. Growth factors of platelet-rich autoplasm in reconstructive implantology of degenerative-dystrophic tendon diseases. Medicine in Kuzbass. 2018; 3 (17): 53-57. [Panov A.A. Plateletrich plasma growth factors in reconstructive implantology of musculoskeletal degenerative dystrophic diseases. Medicine in Kuzbass. 2018; 3 (17): 53-57. [in Russian]
6. Petrova N.A. Influence of probiotics on blood indices of rabbits / K.A. Sidorova, K.S. Esenbaeva, N.A. Petrova, A.A. Bektasheva // Bulletin of the Tyumen State Agricultural Academy. Issue 1. - Tyumen. - 2007. - S. 162-163. [in Russian]
7. Anitua E., Sánchez M., Nurden A.T. et al. Platelet-released growth factors enhance the secretion of hyaluronic acid and induce hepatocyte growth factor production by synovial fibroblasts from arthritic patients // Rheumatology (Oxford). - 2007. - 46(12). - p. 1769-17. [in Russian]
8. Cole B.J., Karas V., Hussey K. et al. Hyaluronic Acid Versus Platelet-Rich Plasma: A Prospective, Double-Blind Randomized Controlled Trial Comparing Clinical Outcomes and Effects on Intra-articular Biology for the Treatment of Knee Osteoarthritis // Am. J. Sport Med. - 2017. - 2017. - 45(2). - p. 339-346.
9. Maniscalco P The "Cascade" membrane: a new PRP device for tendon ruptures. Description and case report on rotator cuff tendon Maniscalco P, Gambera D, Lunati A, et al. Acta Biomed 2008 Dec;79(3):223
10. Mishra A, Woodall J Jr, Vieira A. Treatment of tendon and muscle using platelet-rich plasma. Clin Sports Med. 2009 Jan;28(1):113-25. doi: 10.1016/j.csm.2008.08.007. PMID: 19064169.
11. Sanchez M, Anitua E, Azofra J, et al. Intra-articular injection of an autologous preparation rich in growth factors for the treatment of knee OA: a retrospective cohort study Clin Exp Rheumatol Sep-Oct 2008;26(5).
12. Maniscalco P. The "Cascade" membrane: a new PRP device for tendon ruptures. Description and case report on rotator cuff tendon. Maniscalco P, Gambera D, Lunati A, Vox G, Fossombroni V, Beretta R, Crainz E. Acta Biomed. 2008 Dec;79(3):223-6.
13. Dallary D., Stagni C., Rani N. et al. Ultrasound-Guided Injection of Platelet-Rich Plasma and Hyaluronic Acid, Separately and in Combination, for Hip Osteoarthritis: A Randomized Controlled Study // Am. J. Sport Med. - 2016. - 44(3).

14. Miloslav Martinec, Helena Hartlova, Darina Chodova Eva Tumova Alena Fucfkova. Selected haematological and biochemical indicators in different breeds of rabbits. ACTA VET. BRNO 2012, 81: 371-375.

15. Abdullaeva U.K. Predicting the risk of atrophic transformation in chronic gastritis using serum pepsinogen // World journal of pharmaceutical research, Faculty of Pharmacy Medical University, Bulgaria, Vol. 8, Iss. 13, 2019, P. 219-228.

16. Abdullaeva U.K., Sobirova G.N., Karimov M.M., Aslonova I.J. The prevalence and possibilities of prevention of noncardial gastric cancer in the Bukhara region // American journal of medicine and medical sciences, 2020, 10(9), P. 679-681.

17. Sobirova G.N., Abdullaeva U.K., Nosirova M.S., Aslonova I.J. Evaluation of the gastrointestinal mucosa by the OLGA system in chronic atrophic gastritis // Journal of critical reviews, Kuala Lumpur, Malaysia, Vol. 7, Iss. 2, 2020, P. 409-413.

18. Karimov M.M., Sobirova G.N., Abdullaeva U.K., Aslonova I.Zh., Tulyaganova F.M. Possibilities of serological diagnosis of atrophic processes of the gastric mucosa // European Journal of Molecular & Clinical Medicine Vol. 7, Iss. 11, 2020, P. 2955-2960.

19. Karimov M.M., Sobirova G.N., Abdullaeva U.K. Chronic gastritis and carcinogenesis issues // Herald of Pancreatic Club, 2019. Iss. 45 (4). P. 65-70. [in Russian]

20. Sobirova G.N., Abdullaeva U.K. Immunopatogenesis of chronic gastritis and its role in carcinogenesis // Journal of Biomedicine and Practice, 1 (4). P. 40-44.

21. Karimov M.M., Sobirova G.N., Abdullaeva U.K., Aslonova I.Zh., Tulyaganova F.M. Possibilities of Serological Diagnosis of Atrophic Processes of the Gastric Mucosa // Annals of the Romanian Society for Cell Biology, , Vol. 25, Issue 1, 2021, Pages. 6168 – 6174.

22. Abdullaeva U.K., Shadjanova N.S. Using the OLGA system in chronic atrophic gastritis // New day in medicine, 2020, №2, P. 9-12.

23. Abdullaeva U.K. The value of interactive teaching methods in improving the level of clinical knowledge of students // Medical education and professional development. 2019, №1 (33), P. 29-32. [in Russian]

24. GN Sobirova, UK Abdullaeva Chronic gastritis and carcinogenesis issues // Central Asian Problems of Modern Science and Education. 2019, Iss. 4, №2, P. 159-172

25. Orziev Zavkiddin Mansurovich, Abdullaeva Umida Kurbanovna, Nurkhanova Nilufar Odiljonovna Study of the effectiveness of cholelitholytic therapy in patients with cholelithiasis, taking into account the type of violation of the contractility of the gallbladder // Science of the Young - Eruditio Juvenium. 2015. №4. P. 50. [in Russian]

26. Karimov M.M., Sobirova G.N., Abdullaeva U.K., Aslonova I.Zh., Tulyaganova F.M. Serological Diagnosis of Atrophic Processes of the Gastric Mucosa // The American Journal of Medical Sciences and Pharmaceutical Research, Vol. 2, Issue 12, 2020, Pages. 118-124

27. DB Mirzaeva, UK Abdullaeva, RR Boboeva The importance of interactive teaching methods in improving the level of clinical knowledge of students // Central Asian Problems of Modern Science and Education Vol. 4, Issue 2, 2019, Pages. 159-166

28. MM Karimov, ST Rustamova, ZhA Ismailova, UK Abdullaeva, ZZ Saatov Diagnostic efficacy of C14 breath test in Helicobacter pyloriosis // Cardiovascular therapy and prevention. 2019. Vol. 18, Issue S1, P. 85-86

29. Abdullaeva U.K., Jalolova V.Z. Study of the effectiveness of cholelitholytic therapy in patients with cholelithiasis, taking into account the type of violation of the contractility of the gallbladder // Bulletin of the Council of Young Scientists and Specialists of the Chelyabinsk Region. 2016. Vol. 5, Issue 4(15), P. 85-86 [in Russian]

30. Orziev Z.M., Abdullaeva U.K. Regional causes of extrahepatic "Subtransaminasemia" // Biology and integrative medicine 2016, №3. P. 28-40. [in Russian]

31. Abdullaeva U.K., Mirzaeva D.B. Regional prospects for metabolic therapy for stable senocardia Summary. // Bulletin of the South Kazakhstan Medical Academy 2019. P. 74-76 [in Russian]

32. Orziev Z.M., Abdullaeva U.K., Yuldasheva D.H. Method for early prediction of the efficiency of cholelytic therapy based on dynamic control of bild pH indicators in patients with cholelystone disease // Innovative development of modern science. 2014. P.76-79 [in Russian]

33. Orziev Z.M., Abdullaeva U.K. Relationship between the effectiveness of cholelitholytic therapy and the state of contractility of the gallbladder // Bulletin of the Council of Young Scientists and Specialists of the Chelyabinsk Region. 2015. №3(10) [in Russian]

34. Orziev Z.M., Abdullaeva U.K. The effectiveness of cholelitholytic therapy for cholelithiasis // Health is the basis of human potential: problems and ways to solve them. 2015. Iss. 10. №2. P. 610-612. [in Russian]

35. Abdullaeva U.K. Predicting the risk of atrophic transformation in gastritis associated with chronic Helicobacter pylori // abstract of PhD dissertation on medical sciences. Tashkent. 2021. 46-p.